

Traumatic Carotid Artery Dissection

Case Report

Clinical Scenario

A 48 year-old male with no significant past medical history presented to a small community Emergency Department (ED) complaining of a “sore throat” worsening for three days and new onset right-sided ptosis later the same day. The patient had fallen while skiing four days prior to the ED visit and stated that he felt that he had hyperextended his neck at the time of the fall. He had seen his primary care physician and was offered symptomatic treatment of his sore throat and was instructed to follow-up if his condition changed or worsened. Upon arrival in the ED, the patient’s vital signs were within normal limits and there were no other physical findings other than the right-sided ptosis.

Given the patient’s complaints of neck pain coupled with neurologic symptoms, the ED physician was very concerned that the patient could have a vascular injury. The computerized tomography technician was notified to come in from home and, while waiting, the physician performed a bedside focused ultrasound of the patient’s neck. The ZONARE portable ultrasound system was wheeled into the room and, using a high frequency 10MHz linear array transducer, abnormal findings were immediately observed in the common carotid artery. High resolution B-mode imaging revealed an intimal flap along the near wall of the vessel (arrow) and an intramural hematoma along the far wall (orange oval) (Figure 1). These findings quickly confirmed the diagnosis of a carotid dissection with thrombus formation. Bi-directional flow, a hallmark sonographic finding in carotid dissection, was clearly visualized in transverse section using high-sensitivity color Doppler imaging (Figure 2). Transverse section in another case of traumatic carotid dissection revealed the classic, characteristic intimal flap that was clearly resolved using a ZONARE point of care ultrasound system.

The interventional neurology team was quickly recruited and a follow-up CTA was performed to confirm

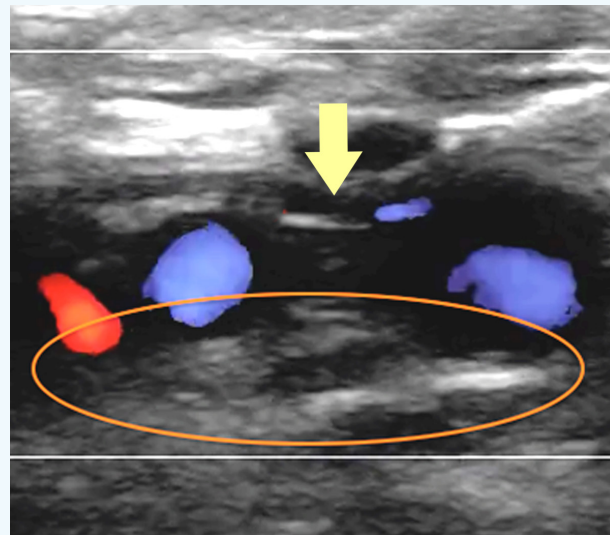


Figure 1. An intimal flap is seen on the near wall of the common carotid artery (arrow). Intramural thrombus is identified on the far wall (orange oval).

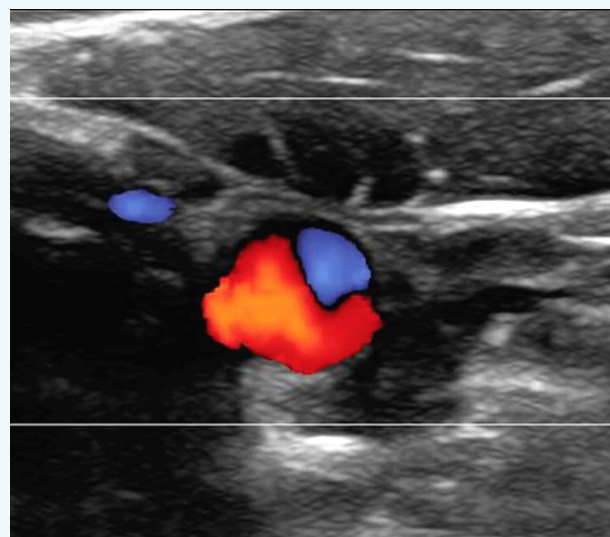


Figure 2. Transverse section through the common carotid artery using color Doppler imaging demonstrates hallmark bi-directional flow in the area of dissection.

the diagnosis and to further delineate the extent of injury. The patient was placed on anticoagulation and his symptoms gradually improved. He was discharged on hospital day four.

ZONE Sonography™ Technology Solution:

Proprietary Dynamic Pixel Focusing™, available only on ZONARE ultrasound platforms, offers clinicians unparalleled sonographic image quality. Each image is focused at every point on both transmit and receive without compromising temporal performance. In this case, the exquisite spatial resolution enabled clear visualization of a small but significant abnormality in the carotid artery.

Vascular ultrasound exams may be an advanced application for many ED physicians, however, Zonare's powerful and unparalleled imaging capabilities gave this doctor the clinical information and confidence necessary to make an accurate and rapid diagnosis which expedited the care of this patient.

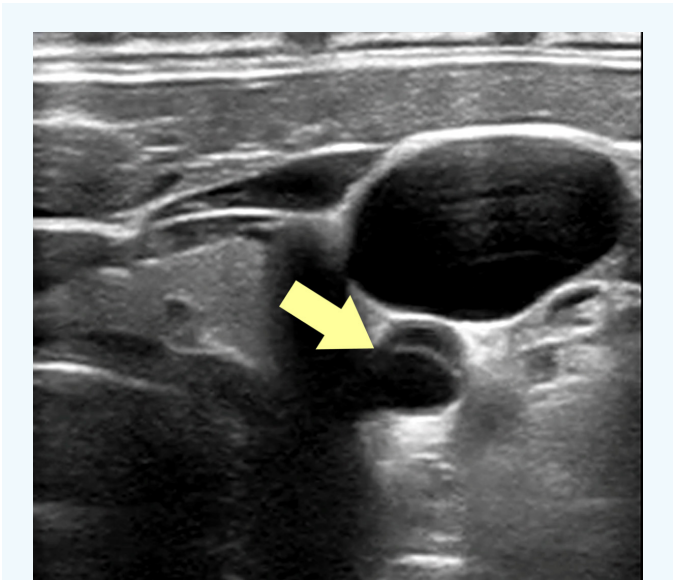


Figure 3.
A different case of carotid dissection demonstrates a classical intimal flap (arrow).

Author

Christopher Raio, MD, MBA, RDMS, FACEP

Past Chair, SAEM Ultrasound Interest Group
Past-Chair, ACEP Ultrasound Section
Senior member, AIUM



ZONARE Medical Systems, Inc
420 N. Bernardo Ave
Mountain View, CA 94043-5209

Phone: (650) 230-2800
Email: info@zonare.com
www.zonare.com