

Smart Planes

Computer-Aided Solution
for Examination of Fetal Brain



Smart Planes

Computer-Aided Solution for Examination of Fetal Brain

Yaoxian Zou, MS, Muqing Lin, PhD, Kyle Brennan, MD and Yi Xiong, MD

Shenzhen Mindray Bio-Medical Electronics Co., Ltd., China
Shenzhen People's Hospital, China

Introduction

Clinical value of CNS screening

Central nervous system (CNS) malformations are one of the most common congenital abnormalities. Ultrasound has been used for nearly 30 years as the major imaging modality to help diagnose fetal CNS anomalies [1]. Currently, the standard 2D planes used for ultrasound assessment of the central nervous system in fetuses include the Trans-Cerebellar Plane (TCP), the Trans-Thalamic Plane (TTP), and the Trans-Ventricular Plane (TVP). However, with the use of 3D, the acquisition of the Median or Mid-Sagittal Plane (MSP) adds a new and very clinically useful perspective.

The orientation of the Mid-Sagittal Plane provides a unique view of the intracranial structures such as the corpus callosum (CC) and an axial view of the cerebellar vermis (CV). Several studies[2~8] have proven that the observation from the MSP is critical for the clinical diagnosis of Agenesis of the Corpus Callosum(ACC) and Dandy-Walker Syndrome.

TCP, TTP, and TVP are the most critical planes in a fetal CNS examination. The anatomic landmarks in these planes include the cavum septi pellucidi (CSP), thalami, cerebellum, cisterna magna, and lateral ventricles. In addition to observing the morphology of these structures, measurements of this anatomy is also important to prenatal ultrasonography. The standard measurements of the fetal head include the head circumference (HC), biparietal diameter (BPD), and occipitofrontal diameter (OFD) from the TTP. The width of the cisterna magna (CM) and transcerebellar diameter (TCD) are obtained from the TCP and the width of the lateral ventricles (LVW) from the TVP.

Challenges of CNS screening

Unfortunately, due to the various imaging conditions such as poor fetal position, acoustic shadowing, and operators' scanning skills [5], the MSP is particularly difficult to obtain from a 2D ultrasound. Xie et al[6] showed that a successful acquisition of the MSP from 2D ultrasound is only about 35.5%. Because of the low acquisition rate of MSP in 2D scans, clinicians can only conduct indirect examination based on several transverse planes of the fetal brain in many cases, leading to a high rate of misdiagnosis of the CC or CV related diseases.

Currently, the common workflow used to acquire these standard images with measurements is a physically demanding and time consuming process. The sonographer must image each of the required transverse planes individually and make the measurements on the appropriate anatomy manually. This can be challenging since some of the views can be difficult if not impossible to acquire in 2D, such as the MSP, and the measurements are user dependent which can be subjective and inconsistent. The constant manipulation of the transducer over extended periods of time has been proven to increase the possibility of developing Repetitive Stress Injuries.

Today, 3D ultrasound has been widely accepted for fetal imaging and the major advantage is the ability to obtain many views from one volumetric dataset. However, many physicians have not yet adopted the use of 3D acquisition in practice due to a lack of knowledge required for 3D acquisition versus 2D imaging, the difficulty in recognizing some views of the anatomy from a totally unfamiliar display such as the C Plane, and the need to learn new methods for rotating, translating, and manipulating the 3D volumes which can be very daunting and time consuming initially. For example, according to a recent report [7], for a skilled sonographer to manually acquire the MSP it usually takes between 65~186s with the average time being 90.7 ± 8.6 s.

Therefore, a faster and more user friendly method to automatically display the standard planes with the required measurements in a fetal CNS examination could significantly boost both the quality and efficiency of clinical diagnosis. Smart Planes, an innovative solution for automatic detection of standard fetal CNS planes, is released on Mindray's latest premium ultrasound imaging system to greatly improve the efficiency and accuracy of fetal CNS studies.

Principle of Smart Planes

Machine Learning, a field of computer science, allows for the construction of computer algorithms that can learn from and make predictions on data. Learning-based detection is an innovative methodology in medical image analysis that applies the theories of machine learning and pattern recognition to detect interested anatomic structures. The basic idea of learning-based detection is to simulate the visual recognition process of a human by automatically selecting the appropriate features from the training dataset and further constructing the mathematical model to distinguish the attribution of input samples.

For Smart Planes, the training dataset consisted of over 5000 images of the general standard planes in fetal CNS (i.e., MSP, TCP, TVP, and TTP) that contain important anatomical structures (i.e., cerebellum, cavum septi pellucidi, corpus callosum, lateral ventricle and so on). The image features were first extracted using advanced image processing algorithms and then further applied to the training/learning algorithms to generate the final detection model. Based on the trained detection model, Smart Planes can automatically provide the likelihood of the input plane being one of the standard planes (MSP/TCP/TVP/TTP).

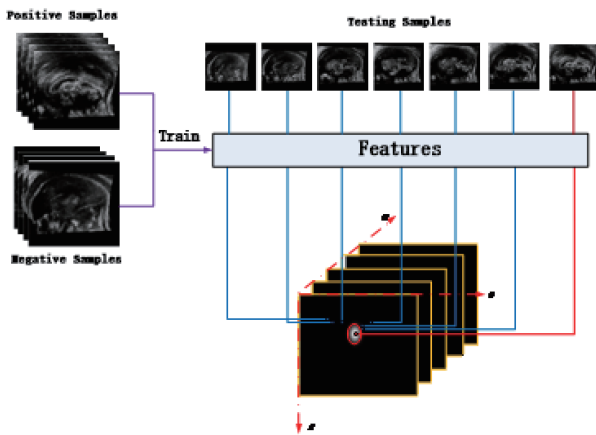


Fig.1 Workflow of standard plane detection.

Fig.1 shows the workflow of standard plane detection. The optimal standard plane is detected based on the features learned from positive and negative samples. In practice, MSP is first detected and the transverse planes (TCP, TTP, and TVP) are searched along the direction perpendicular to MSP. The search strategy is based on human anatomy which can both save the computational time and improve the robustness of detection.

In volumetric geometry, an image plane in 3D ultrasound data is given by:

$$\rho = \cos\theta \cos\varphi X + \sin\theta \cos\varphi Y + \sin\varphi Z$$

The algorithmic goal of Smart Planes is to calculate the appropriate parameters $[\rho\theta\varphi]$ that generates a target plane that fits the detection model best.

Benefit of Smart Planes

With the artificial intelligence based on 5000-case big data, Smart Planes provides a user-friendly tool that greatly improves scanning efficiency through increased accuracy coupled with automated operation. As illustrated in Fig.2, the traditional method usually involves a lot of manual adjustment which is user-dependent and time consuming, even for experienced doctors it could take minutes to find the standard planes; while with Smart Planes, with a simple button click on a 3D fetal brain volume image, the standard CNS scanning planes (MSP, TCP, TTP and TVP) and a range of related anatomical measurements (BPD, HC, OFD, TCD, CM and LVW) are obtained immediately.

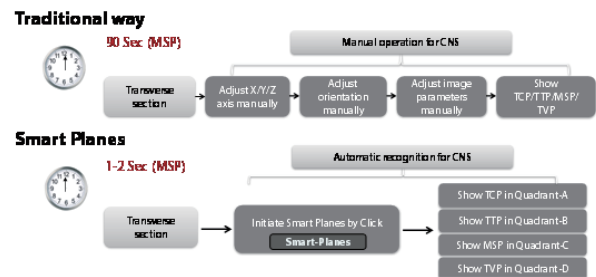


Fig.1 Compared with traditional way, Smart Planes is more intelligent and more time-saving to provide automatic and accurate detection of standard fetal CNS planes.

Case study

Smart Planes was clinically validated over 275 cases in Shenzhen People's Hospital and Hubei Women and Children's Hospital. Specifically, the cohort of the clinical trial consisted of 240 normal cases and 35 abnormal cases. These abnormal cases included Agenesis of the Corpus Callosum (ACC), Dandy-Walker Syndrome, dilatation of the Cisterna Magna and so on (see Table.1). Smart Planes was able to automatically detect the four general standard planes (MSP, TCP, TTP, and TVP) and calculate the related 6 measurements (BPD, OFD, HC, TCD, CM and LVW) within 1.5s. The rate of successful detection was up to 95% for normal cases and 85% for abnormal cases. All the abnormal cases and 10 normal cases were also verified using MRI, and the MRI findings supported the diagnosis based on Smart Planes.

Table.1 The types and numbers of abnormal cases

| Abnormal Type | Case Number |
|--|-------------|
| Agenesis of the Corpus Callosum(ACC) | 15 |
| Dandy-Walker Syndrome | 5 |
| Other types of abnormal cases (dilated Cisterna Magna,Hydrocephalus, Fetal Lateral Ventriculomegaly and so on) | 15 |

Case1:

Dandy-Walker Syndrome and ACC

GA:24W0D Age:32

A fetus with both Dandy-Walker Syndrome and ACC is shown in Fig. 3. The size of the cerebellar vermis is smaller than normal and the shape of the cerebellum is different from normal (MSP, TCP in Fig.3A). What's more, the cavum septi pellucidi is very small and the length of corpus callosum is very short (MSP in Fig.3A). MRI confirmed these findings (Fig.3B).

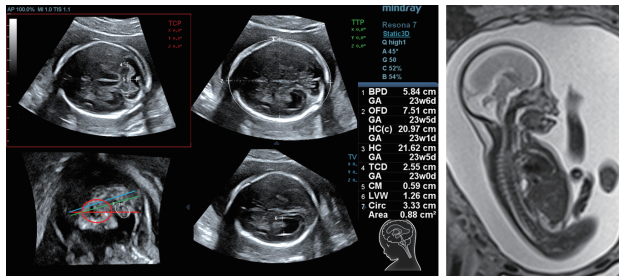


Fig.3 Dandy-Walker syndrome and ACC of case 1, the abnormal development in cerebellar vermis, cerebellum, cavum septi pellucidi, and corpus callosum are clearly displayed with accurate measurements.

Case2:

Misdiagnosis as Dandy-Walker Syndrome in 2D - Diagnosed Correctly from Smart Planes

GA :24w0D Age:33

Fig. 4 shows a case which was misdiagnosed as Dandy-Walker Syndrome from 2D ultrasound in another hospital. After acquiring the MSP using Smart Planes in Shenzhen People's Hospital, the cerebellar vermis was found and the size was normal, which means the fetal vermis was indeed normal (MSP, TCP in Fig.4 A). The patient also had an MRI which confirmed the findings using Smart Planes (Fig.4 B).

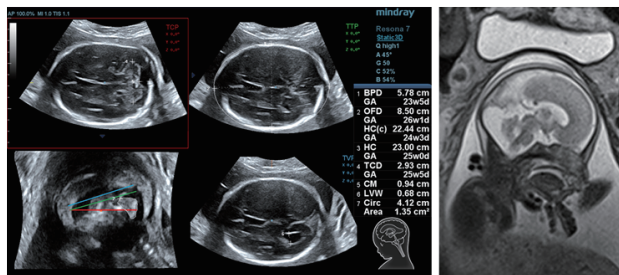


Fig.4 MSP and MRI images of case 2, which was misdiagnosed as Dandy-Walker Syndrome from 2D ultrasound, but was corrected by Smart Planes.

Conclusions

Mindray provides a robust solution of the automated detection of the TCP, TTP, MSP, and TVP as well as the automated measurements of the BPD, OFD, HC, TCD, CM, and LWV for evaluation of the fetal central nervous system through Smart Planes. The methodology was specifically designed to enable the auto-detection of the 4 standard planes and the auto-calculation of the 6 regular measurements with both precision and speed (less than 1.5 second). The clinical trials have demonstrated Smart Planes can significantly simplify the process of fetal brain examination (20-30w) and assist doctors with an efficient and accurate diagnosis.

Reference

- [1] The ISUOG Education Committee, *Sonographic examination of the fetal central nervous system: guidelines for performing the 'basic examination' and the 'fetal neurosonogram'*, *Ultrasound Obstet Gynecol*, 2007.
- [2] Vinals F, Munoz M, Naveas R, Schalper J, Giuliano S, *The fetal cerebellar vermis: anatomy and biometric assessment using volume contrast imaging in the C-plane(VCI-C)*, *Ultrasound Obstet Gynecol*, 2005.
- [3] D'Addario V, Pinto V, Di Cagno L, Pintucci A. *The midsagittal view of the fetal brain: a useful landmark in recognizing the cause of fetal cerebral ventriculomegaly*. *J Perinat Med*, 2005.
- [4] Chang C, Chang F, Yu C, Ko H, Chen H. *Three dimensional ultrasound in the assessment of fetal cerebellar transverse and antero-posterior diameters*. *Ultrasound Med Biol*, 2000.
- [5] Pilu G, Segata M, Chi T, Carletti A, Perolo A, Santini D, Bonasoni P, Tani G, Rizzo N, *Diagnosis of midline anomalies of the fetal brain with the three-dimensional median view*, *Ultrasound Obstet Gynecol*, 2006.
- [6] Xie H, Cai D, Zhu Y, Li L, *Study on the development of fetal cerebellar vermis with the third plane image of three-dimensional ultrasonography*. *Chinese Journal of Ultrasound in Medicine*, 2006.
- [7] Yang J, Yuan J, Qu X, *Three-dimensional ultrasound visualization for fetal corpus callosum and cerebellar vermis midline image*, *Chin J Med Imaging Technol*, 2012.
- [8] Yi Y, Xiong Y, Lin Q, Jiao Y, Xu JF, Zou YX, Lin MQ, *Preliminary application of intelligent three-dimensional ultrasound imaging of fetal cranial mid-sagittal view*. *Chin J Ultrasonogr*, Vol 23, No.3, 2015.

Mindray Building, Keji 12th Road South,
High-tech Industrial Park, Nanshan, Shenzhen 518057, P.R. China
Tel: +86 755 8188 8998 Fax: +86 755 26582680
E-mail: intl-market@mindray.com www.mindray.com

mindray | healthcare with reach are registered trademarks or trademarks owned by Shenzhen Mindray Bio-medical Electronics Co., LTD.
©2015 Shenzhen Mindray Bio-Medical Electronics Co., Ltd. All rights reserved. Specifications subject to changes without prior notice.
P/N: ENG-Smart Planes-Computer-Aided Solution for Examination of Fetal Brain-210285x4P-20160414

mindray