

Testicular Torsion: ED Ultrasound Diagnosis Improves Outcomes.

Case Report

Full Story

An otherwise healthy 23 year old man awoke with severe right testicular pain. The pain progressively increased throughout the day with acute worsening three hours prior to presentation at the Emergency Department (ED). On physical examination his right hemiscrotum was exquisitely tender with the testicle palpated lying high and transversely. A tentative diagnosis of testicular torsion was made based on the classic clinical findings in this young man.

Bedside ultrasound examination was performed in the ED with the ZONARE Z.One PRO imaging platform which revealed an enlarged right testicle with a heterogeneous sonographic texture, thickened scrotal skin (Figure 1), and a markedly dilated and edematous epididymis and spermatic cord (Figure 2). Power Doppler imaging failed to demonstrate blood flow within the spermatic cord or testicular parenchyma (Figure 3) – typically a pathognomonic finding when using a highly sensitive Doppler ultrasound imaging system.

The patient was transported to the surgical suite within thirty-five minutes after admission to the ED where the diagnosis of testicular torsion was confirmed. The right testicle had twisted four times on the spermatic cord pedicle. After detorsion, blood flow returned to the testicle and it was determined to be viable. Because of a quick and accurate diagnosis, the testicle was saved and the patient enjoyed an uneventful recovery.

Testicular torsion constitutes a true urological emergency that requires quick and accurate differentiation from other sources of scrotal pain. It is a common condition, particularly in adolescent and young adult males accounting for over a quarter of cases of acute scrotum. Delayed diagnosis and management can result in loss of the testicle. While the clinical presentation and physical finding in these

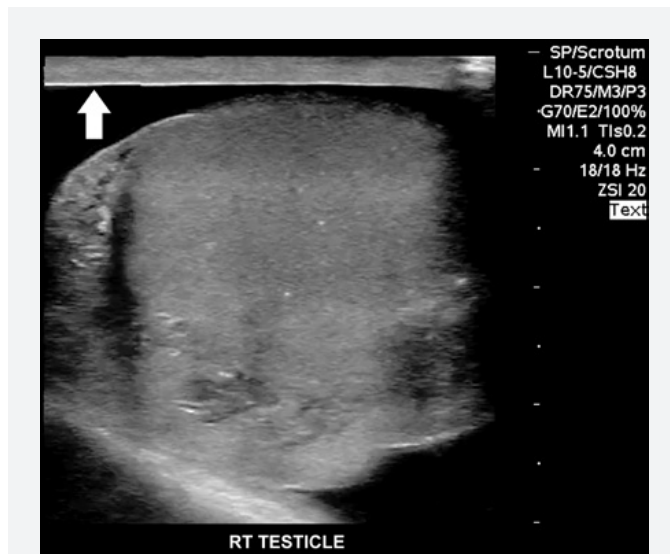


Figure 1. Enlarged, heterogeneous right testicle with thickened scrotal skin (arrow).

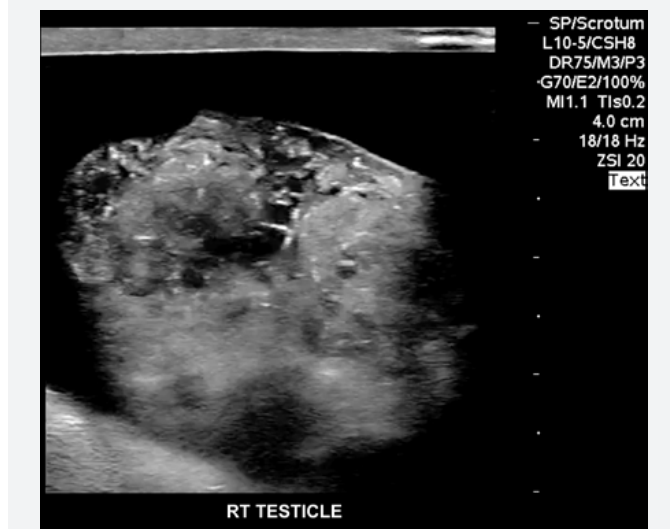


Figure 2: Sagittal scan through the enlarged, edematous epididymis and spermatic cord.

patients is highly suggestive of a torsed testicle, high resolution B-mode ultrasound imaging coupled with exquisitely sensitive color and power Doppler modes, both hallmarks of the ZONARE line of products, has been validated as a routine preoperative diagnostic tool in assessment of patients presenting to the ED with acute scrotum.

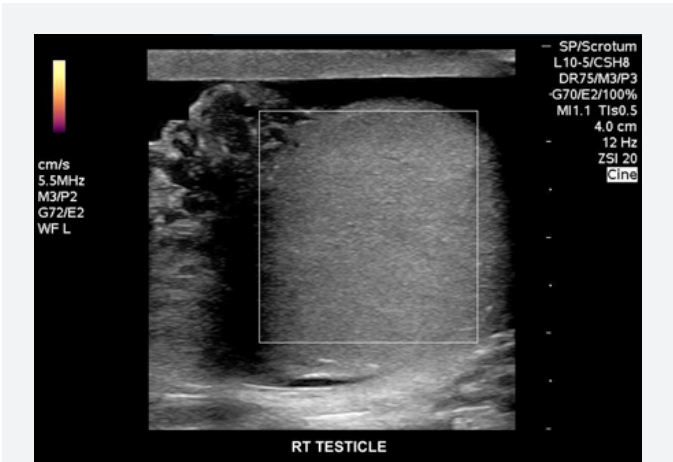


Figure 3: Power Doppler imaging fails to demonstrate perfusion.



Author

Gerardo Chiricolo, MD, FACEP
Past Chair, ACEP Ultrasound Section
Chair, Division of Clinical Ultrasound
Director, Division of Emergency Ultrasound
Director, Emergency Ultrasound Fellowship
NY Methodist Hospital



Celebrating 10 Years of Innovation

ZONARE Medical Systems, Inc
420 N. Bernardo Ave
Mountain View, CA 94043-5209
Phone: (650) 230-2800
Email: info@zonare.com
www.zonare.com