

Nerve Sheath Tumor

Case Report

Full Story

High resolution B-mode ultrasound is rapidly evolving as an accurate and well-tolerated tool in the musculoskeletal imaging armamentarium. The ability to identify and differentiate subtle tissue variations in real-time requires higher frequency ranges and more robust digital signal processing capabilities than have historically been possible on commercially available sonographic imaging instruments. The adaptation of ZONE Sonography™ Technology and its inherent ability to maintain exquisite spatial and contrast resolution at all imaging depths particularly when using very high frequency ultrasound beams has proven ideally suited to dynamic musculoskeletal diagnosis.

Consider the following illustrative example:

A 53 year old male presented to an orthopedic surgeon for shoulder pain. An MRI at an outside institution demonstrated a tear of the supraspinatus tendon as well as the superior fibers of the subscapularis tendon with associated subluxation of the long head of the biceps tendon (not shown). Incidental note was made of a lesion adjacent to the neurovascular bundle. An orthopedic oncologist who consulted on the case asked us to review the images.

The imaged lesion measured 2.5 cm in maximum dimension and was hyperintense on fat suppressed proton density sequences (Figure 1). It had a peculiar central rim enhancement that was nonspecific on post-contrast imaging (Figure 2). No T2 fat saturated images were obtained. Differential diagnosis included nerve sheath tumor, abnormal lymph node, or less likely, pseudoaneurysm.

A same day ultrasound was performed with the ZONARE ZS3 imaging platform. Using the L14-5w linear array transducer with a mean spatial harmonic operating frequency of 12 MHz, a hypoechoic lesion was identified near the neurovascular bundle. Despite scanning in all planes, no connection could be found between the lesion and any adjacent structures

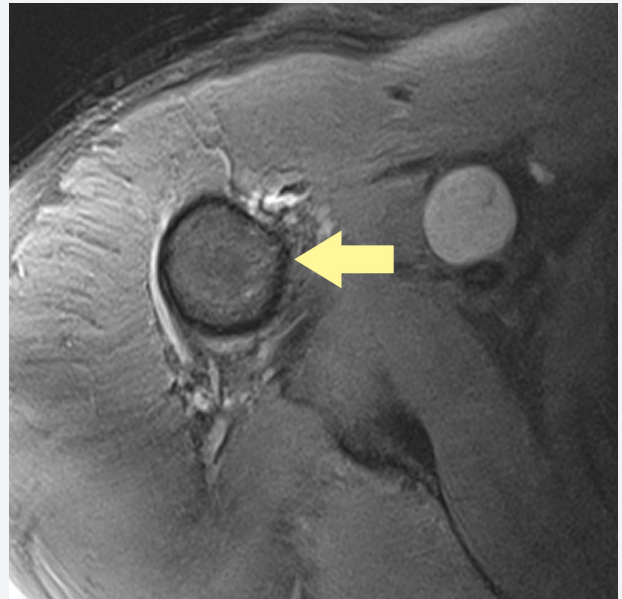


Figure 1. Axial proton density fat suppressed MRI image demonstrating a rounded lesion along the neurovascular bundle (arrow).

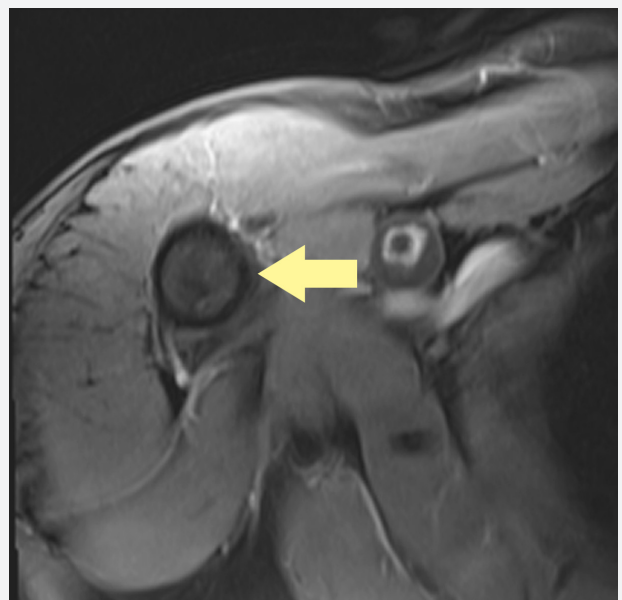


Figure 2. Post contrast image demonstrates atypical central enhancement which is non-specific.

with this probe (Figure 3). No internal blood flow was identified using highly sensitive color or power Doppler imaging making pseudoaneurysm an unlikely diagnosis (Figure 4). The lesion did not have the appearance of a normal lymph node. No identifiable nerves could be seen using any of the frequency ranges available on this transducer.

The L20-5 linear array probe operating at a mean frequency of 18 MHz was then utilized to evaluate the margins of the lesion looking specifically for nerve bundles exiting the mass. Several nerve fascicles could be clearly visualized as linear hypoechoic structures at the distal aspect of the lesion (Figure 5). The lesion was too deep for adequate identification of nerves on the proximal end of the lesion. These findings are diagnostic for nerve sheath tumor.

The 20 MHz linear array probe (L20-5) available with the ZONARE ZS3 premium ultrasound system is leading the industry in musculoskeletal imaging. Its great utility lies not only in the unmatched resolution its images provide of superficial structures but also in its ability to maintain adequate signal strength and pixel-by-pixel-focusing at depths where other probes fail.

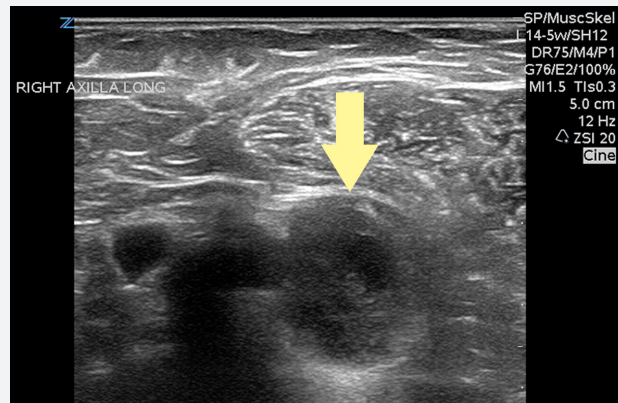


Figure 3. Sonographic image using a linear array transducer with a mean spatial harmonic operating frequency of 12 MHz demonstrates a hypoechoic lesion near the neurovascular bundle.

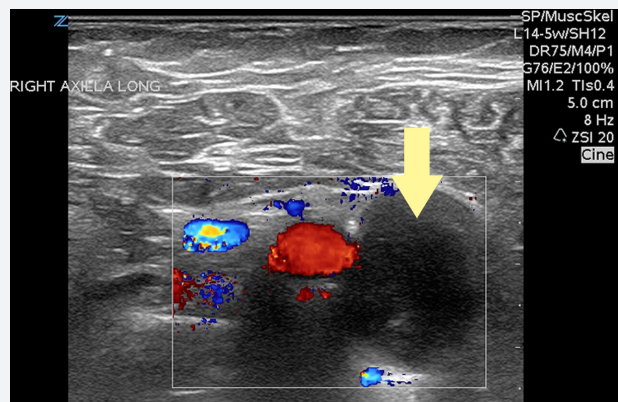


Figure 4. Transverse high sensitivity color Doppler image through the lesion fails to demonstrate internal blood flow ruling out pseudoaneurysm.

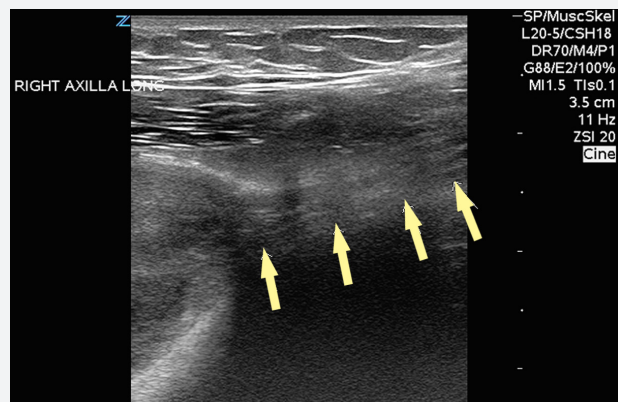


Figure 5. Using a 20 MHz linear array probe (L20-5) clearly demonstrates a fibular structure emanating from the distal aspect of the lesion.

Author

Elliott Brown, MD

Assistant Professor, Yale School of Medicine, Diagnostic Radiology

Assistant Program Director, Yale Diagnostic Radiology Residency



Celebrating 10 Years of Innovation

ZONARE Medical Systems, Inc
420 N. Bernardo Ave
Mountain View, CA 94043-5209

Phone: (650) 230-2800
Email: info@zonare.com
www.zonare.com