

Sound Touch Elastography

A New Solution for
Ultrasound Elastography

mindray
healthcare within reach

Sound Touch Elastography

A New Solution for Ultrasound Elastography

Shuangshuang Li

Introduction

In recent years there has been great interest in measuring the stiffness of tissue in vivo. Indeed, over the past 20 years, different elasticity imaging approaches have been developed around the world[1-4]. Ultrasound elasticity imaging adds mechanical information to conventional diagnostic ultrasound and extends patient diagnostic information. Now more and more doctors have proven its value in many clinical applications, especially in cancer diagnosis[4-8]. Strain elastography has been popular for a long time, providing 2D strain imaging of the ROI (region of interest). Under the same pressure, lower strain corresponds to a harder medium. However, under different pressure, the same tissue may show different strain imaging. Practitioners therefore need more experience to get more reliable images.

Shear wave elastography has gained more attention in recent years, providing quantitative stiffness measurement by displaying the shear wave propagation speed or the tissue mechanical modulus, such as shear modulus, and Young's modulus, which is most often used to quantify the stiffness. A high Young's modulus indicates high stiffness. For a linear, elastic, isotropic medium, Young's modulus E can be estimated by

$$E = 3G = 3 \rho c_s^2$$

where G is the shear modulus that quantifies how the medium shape changes, ρ is the density, and c_s is the speed of shear wave. So, when a shear wave propagates, a high speed indicates a stiff medium, and a low speed indicates a soft one.[8-10]

Shear Wave elastography is a promising technique for non-invasive quantification of tissue stiffness on an absolute scale. However, there are still challenges to get better penetration under real time shear wave elastography. To improve the penetration and to minimize the influence of noise, Mindray has developed an innovative approach for better imaging results based on shear wave..

Acoustic Radiation Force and Shear Wave

The Sound Touch Elastography (STE) technology on the Mindray Resona 7 ultrasound system is a new approach developed to display a real-time stiffness image of the ROI. As shown in Figure 1, a strong intensity, safe ultrasound pulse is used to generate shear waves based on the acoustic radiation force (ARF) in soft tissue[3, 9]. The system then tracks the propagation of the shear waves and continuously detects and records the displacement of tissue induced by the shear waves in the ROI. Eventually, the propagation speeds are calculated and the corresponding elastic modulus derived [11]. Multiple shear waves will be generated in different positions in turn to form a full image.

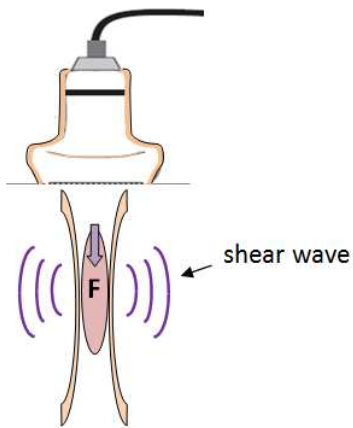


Figure 1: ARF and Shear wave

Ultra-wide Beam Tracking Imaging

Conventional systems are limited to just several ultrasound beams on one ultrasound pulse shot, obtaining information from a very shallow area. However, to calculate the shear wave speed, a larger number of signals from as large an area as possible are needed to accurately locate the position of the shear wave at every single moment during a very short period of time, typically less than several tenths of a millisecond.

Due to the new Ultra-Wide Beam Tracking Imaging technology, shown in Figure 2, the STE on the Resona 7 provides real-time processing of all the signals from an area as wide as 0.2mm~40mm on one shot. It can therefore effectively detect the entire required shear wave information as high as 10KHz per frame. The amplitude of shear wave induced by ARF is very weak, usually several microns to several tens of microns. So it will slightly adjust the position of the receive beams while the shear wave propagates to focus the energy of ultrasound beam as much as possible to improve the quality of receive signals.

Figure 2(b) shows the propagation flows of shear waves captured by Resona 7 in real time at four different time points. When the

propagation speed is different at different depths, the shear wave wavefront is no longer consistent at different depths. The propagation speed of the shear wave is obviously faster in the middle depth range, indicating that the tissue in the middle depth range is stiffer. In addition, as the shear wave gradually propagates into a larger stiff area, the acceleration trend becomes increasingly fierce. However, in an area with even stiffness, the shear wave wavefront keeps stable. The STE/STQ technology ensures that the propagation process of the shear wave can be recorded rapidly, accurately, and completely.

Eventually we can capture all the necessary receive data in less than several tenths of a millisecond. Fast signal capture can reduce the influence of noise induced by other movement during the diagnostic procedure such as breathing and heartbeat, and generate a more focused ultrasound beam. The focused beam results in more centralized energy and therefore improves the penetration.

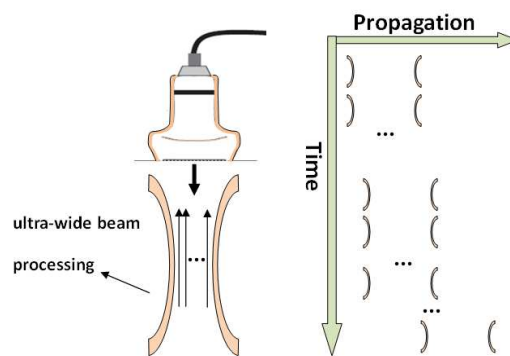


Figure2(a): Ultra-wide Beam Tracking Imaging

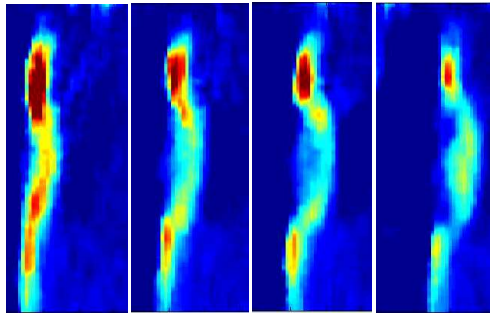


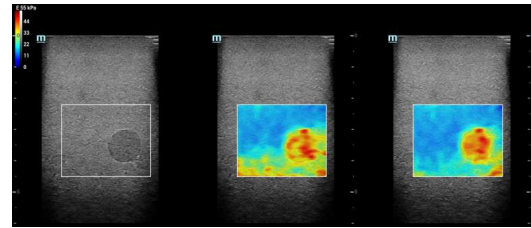
Figure 2(b): propagation flows of shear wave at different time points.

STE Imaging Features

The Shear Wave Elastography (SWE) technology of Resona 7 offers two imaging approaches.

One of them is Sound Touch Elastography (STE), which provides 2D color imaging of tissue stiffness information in the ROI (region of interest), displays elastic distribution of the lesion, and allows required further elasticity value measurement. STE enables users to obtain tissue elasticity distribution details from more intuitive elasticity images, and obtain local quantitative elasticity values of tissues from measurement results.

There are two different display modes available. Users can select real time imaging to acquire a continuous image display in most diagnostic procedures. In some cases with tumors which are very hard, large, and deep, it's also possible to select high quality imaging (HQE) to improve the penetration of shear wave, while only one image is calculated and displayed, as illustrated in Figure 3. The HQE image shows a better lesion shape and less noise in the far field for deeper tumors.



(a) (b) (c)

Figure 3: High quality shear wave elastography imaging (HQE). (a) B mode; (b) HQE: off; (c) HQE: on

Another major feature of STE is that it provides a choice of different types of quantitative elasticity maps for different clinic applications, as illustrated in Figure 4. Among them, the Cs map indicates shear wave speed with values expressed in m/s, while the G map indicates shear modulus with values expressed in kPa, and the E map indicates Young's modulus.

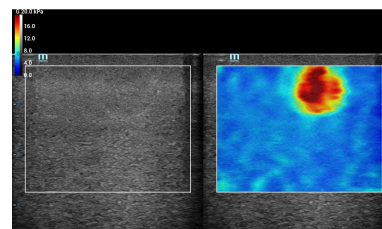


Figure 4: Quantitative elasticity maps

The other approach is Sound Touch Quantification (STQ), which directly performs quantitative measurement on tissue stiffness in the ROI. STQ enables users to directly obtain elasticity values of tissues in the ROI, making quantitative measurement easier and faster. See Figure 5. STQ provides an elasticity measurement result window, which records continuous measurement results. Each result corresponds to a bar on the timeline. The height of a bar represents the average of elasticity in the ROI obtained during the related measurement. This window allows users to check measurement result changes in an intuitive manner.

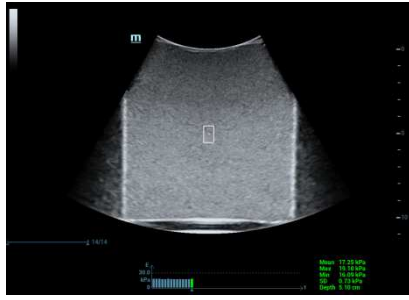


Figure 5: STQ window (phantom with even stiffness)

STQ also provides an inter-frame joint statistics function. After obtaining continuous frames of measurement, a user can use the 'E Avg' knob to select the number of frames for statistics collection, and then select the target frames for statistics collection in the elasticity measurement result window to obtain statistics corresponding to the target frames, for example, median and Inter-Quartile Range (IQR), as shown in Figure 6. Moreover, users can, based on different requirements for clinical applications, specifically select the elasticity mean value (E_{mean}) or elasticity maximum value (E_{max}) of a Region of Interest (ROI) to collect automatic multiframe statistics by using E-Average. This function further improves the accuracy of elasticity measurement results.




Figure 6 Inter-frame joint statistics function (number of frames for statistics collection = 5)

Specially, in the latest version of Resona 7, the automatic interframe joint statistics function can be used in STE without restrictions and the function is called STE-fixed. See Figure 7. In some clinical applications, for example, in the auxiliary diagnosis of liver fibrosis, users may need to control the ROI size and depth to fixed values and desire to make professional judgment based on elasticity distribution images, as

well as perform several repeated measurements. In this case, STE-fixed is a preferred fast examination mean to help physicians to improve the examination efficiency.

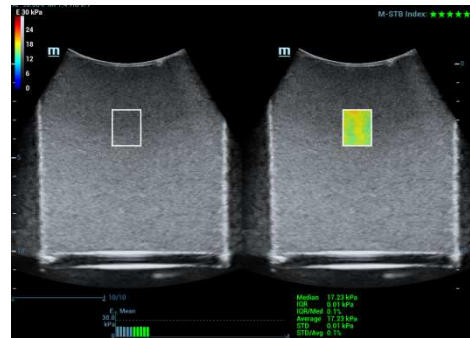


Figure 7: E Average for STE-fixed

The amplitude of the shear wave generated by human tissues is usually very small, and the shear wave elastography technology is sensitive to interference from large-amplitude motion during examination. Especially in the liver examination, patients are often required to hold their breath. In order to obtain stable high-quality images, STE/STQ provides the motion stability index (M-STB Index) to help physicians monitor the motion interference severity in real time. As shown in Figure 8, M-STB Index shows red stars when the motion interference is severe, and shows green stars when the motion interference is low or does not exist. The lower the motion interference, the more the green stars. When M-STB Index is green after several consecutive frames, a message indicating that the shear wave elastography images are collected in the stable state is displayed; when M-STB Index is red, a message indicating that the shear wave elastography images are collected in the motion state and may be unreliable is displayed.

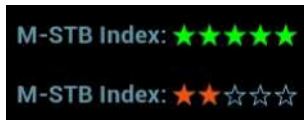

Figure 8: Motion stability index

STE Quantification tools

The STE also provides several effective post-measurement tools to help to analyze the elasticity results. They are very easy to learn and very convenient to operate. For example, once a target region is traced on the B-mode image, the synchronization function helps display the relevant trace on the same region of the elasticity image, as illustrated in Figure 9. This is very helpful in identifying the boundary of the lesion.

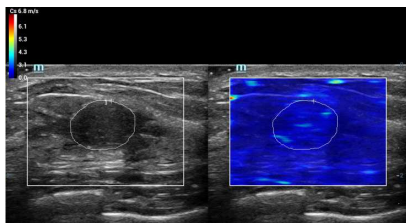


Figure 9: Synchronization function

The Shell quantification toolbox is a unique feature developed for Mindray ultrasound systems. As illustrated in Figure 10, the system calculates and displays all the related elasticity values of the shell area of the selected region, allowing selection of the area near to the outside or inside of the target region.

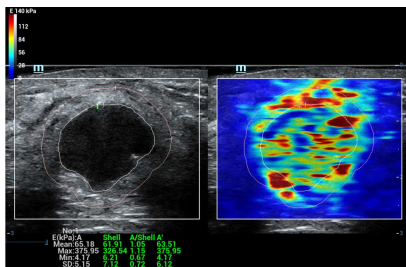


Figure 10: Elasticity measurement of shell quantification toolbox

Furthermore, the elastic histogram

measurement gives statistics for the color-coded elasticity image. And the results of the target region and its shell can both be displayed for comparison, as illustrated in Figure 11 below.

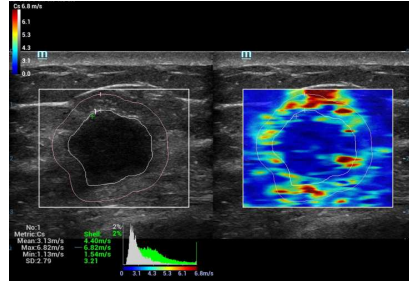


Figure 11: Elasticity histogram of shell quantification toolbox

Of course, analysis of values of the different target regions can be selected independently. In addition, the elasticity ratio function can help to calculate the elasticity ratio between two regions, as illustrated in Figure 12.

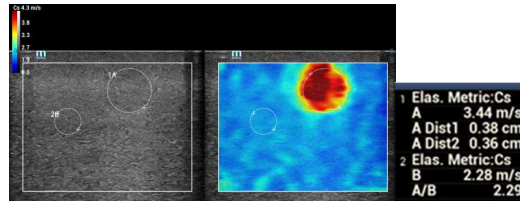


Figure 12: Elasticity ratio of two regions

In particular, the directional ratio is a new feature developed for clinic applications for high anisotropic tissue such as muscle. The shear wave speed may be vastly different in different muscle anatomy sections. In dual-display mode, as illustrated in Figure 13, after the two elasticity images from different anatomy sections are acquired, the directional ratio function allows the quantification of the difference by calculating the ratio of the two shear modulus and provides additional information for diagnosis.

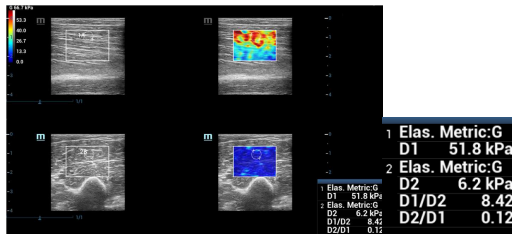


Figure 13: Directional ratio from an examination of biceps brachial

Finally, all the measurement results of STE/STQ can be recorded in the report. For multiple measurement results, you can choose to make further statistical calculations in the report. The elastic data in the report can be conveniently exported as separate files.

Case Study

A clinical study was performed on over 100 breast patients using the STE on Mindray Resona 7 in one of the most famous hospitals in Shanghai. The pathology results showed 32 to be malignant and 50 benign. The results of the study show that the STE provides credible and abundant information to help differentiation of benign and malignant lesions in tumor diagnosis. Most malignant cancers produce images with high stiffness. In one of the clinic examples (Figure 14), the STE image of a breast lesion with all red color inside and around indicates the Young's modulus is above 100kPa via the quantitative map. Furthermore, the stiff area on the STE image is larger than the area of lesion on the conventional B-mode image.

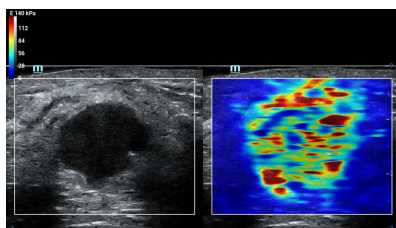
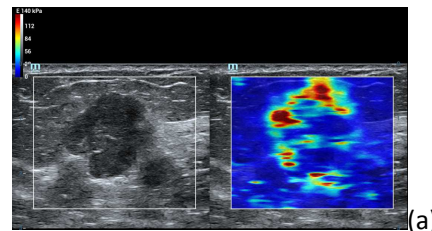
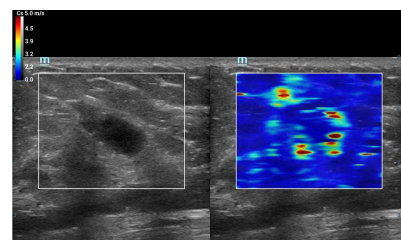


Figure 14: Malignant lesion with high stiffness

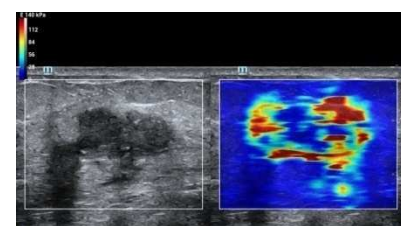
In particular it usually presents a stiff shell pattern in images of most breast malignant lesions. As illustrated in Figure 15a, the red shell of a breast invasive ductal carcinoma reveals a much higher stiffness compared to normal tissue. According to the map, the Young modulus of the shell is above 100kPa while the normal tissue is lower than 40kPa. The shape and the elasticity value of the stiff shell changes with the lesion. As shown in Figure 15b, derived from the examination of a breast carcinoma in situ, the maximum Young's modulus of the shell is above 75kPa while normal tissue is lower than 20kPa. Figure 15c shows the result of a breast carcinoma in situ with small focal micro invasion. The maximum Young's modulus of the shell region is more than 250kPa, while the young's modulus of the normal tissue is lower than that of 20kPa. In 22 clinical examinations of malignant lesions, 20 of them showed images with a stiff shell pattern. With appropriate maps, the stiff shell pattern may become a distinctive, effective pattern to help to identify malignant lesions.



(a)



(b)



(c)

Figure 13 Stiff rim sign (high stiffness in the shell area):

(a) Invasive ductal carcinoma; (b) Breast carcinoma in situ; (c) Breast carcinoma in situ accompanying with small micro invasion

On the contrary, compared with normal tissue, most benign lesions show images with similar stiffness inside, and sometimes slightly higher stiffness around the lesion. The mean Young's modulus inside and around the lesion is often lower than 24kPa. In a few examinations the max value on several points around the lesion is close to 60kPa while the mean value is still low.

Figure 16a is an example of breast adenosis, Figure 16b breast intraductal papilloma and Figure 16c breast fibroadenoma.

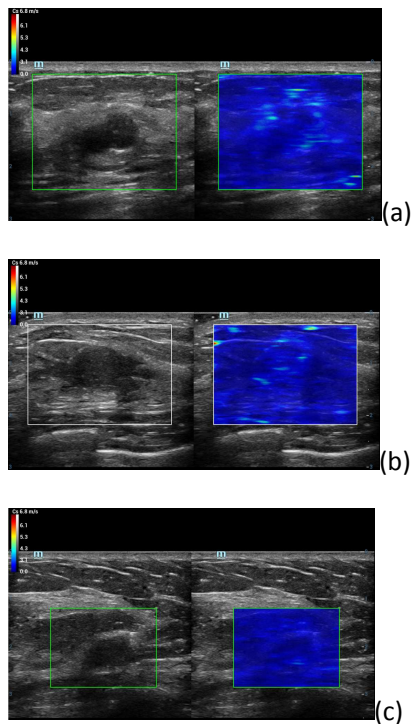


Figure 16: Image of (a)adenosis (b)intraductal papilloma (c) fibroadenoma

In the clinical study, we recorded the shell max and the shell mean values of 41 patients in which the thickness of shell area were chosen to be 3 millimeters. The results are illustrated in Figure 17 and Figure 18. The results show that the majority of max values and mean values of the shell area of

malignant lesions are higher than benign lesions. The average of max values of the shell area from malignant lesions is around 165kPa (distribution from 50kPa to 300kPa), while the average of max values of the shell area from benign lesions is around 64kPa (distribution from 10kPa to 110kPa). The average of mean values of the shell area from malignant lesions is around 31kPa (distribution from 10kPa to 63kPa), while the average of the mean values of the shell area from benign lesions is around 16kPa (distribution from 3kPa to 30kPa).

If 98 kPa is used as a critical value for judging whether a breast tumor is benign or malignant, the maximum sensitivity and specificity in the judgment of benign and malignant lesions can be up to 85% and 95% respectively in the case of 3 mm shell area, and the Area Under the Receiver Operating Characteristic curve (AUROC) can be as high as 0.90. More accurate critical values and ROCs can be obtained if the clinical study is carried out on a larger number of samples. Different critical values can be obtained if different shell thicknesses or measurement observation targets (for example, shell mean value) are adopted.

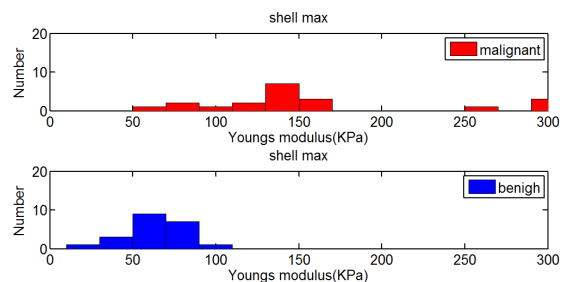


Figure 17: Max values of the shell area

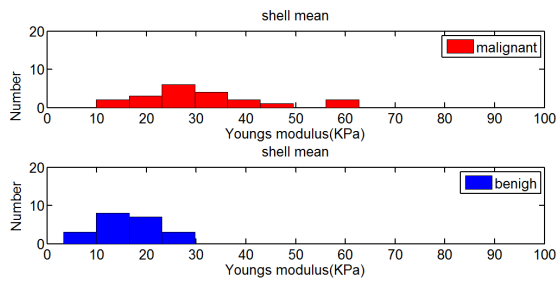


Figure 18: Mean values of the shell area

Therefore, in the regular breast ultrasound diagnosis, after the two-dimensional gray scale ultrasound diagnosis, the further STE/STQ shear wave elasticity imaging (SWEI) may help doctors improve their diagnosis confidence. In particular, when the BIRADS is 4a or above, the doctor will recommend the patient to further receive a needle biopsy. Supplementation with the SWE helps prevent a lot of unnecessary needle biopsies. Figure 19 shows a case in which the BIRADS is 4a. In this case, the STE result indicates the high possibility of the benign lesion. The final pathological result is fibroadenoma, which matches the STE result. If the BIRADS of the patient is changed from 4a to 3 according to the STE result, the patient does not need to receive the needle biopsy.

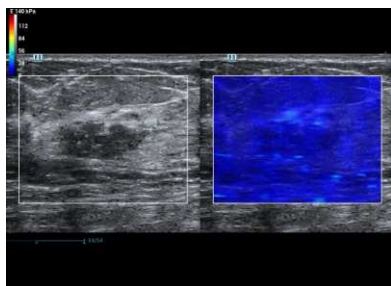


Figure 19: Breast fibroadenoma, the BIRADS is 4a, and the STE image indicates the possibility of the benign lesion

Case Study – Application to Liver

During clinical application to liver, STE and STQ of Resona7 also show their values in non-invasive measurement of the degree of hepatic fibrosis. Figure 20 shows the STE measurement results of patients without

hepatic fibrosis, patients with obvious hepatic fibrosis, and patients with hepatic cirrhosis. As hepatic fibrosis develops, the STE images change significantly in color and the elasticity value increases. Based on the preset quantitative scales of the system, the STE image of a liver without hepatic fibrosis or with mild hepatic fibrosis is evenly blue, the STE image of a liver with significant or severe hepatic fibrosis contains many green spots, and the STE image of a liver with hepatic cirrhosis mainly contains yellow and red spots.

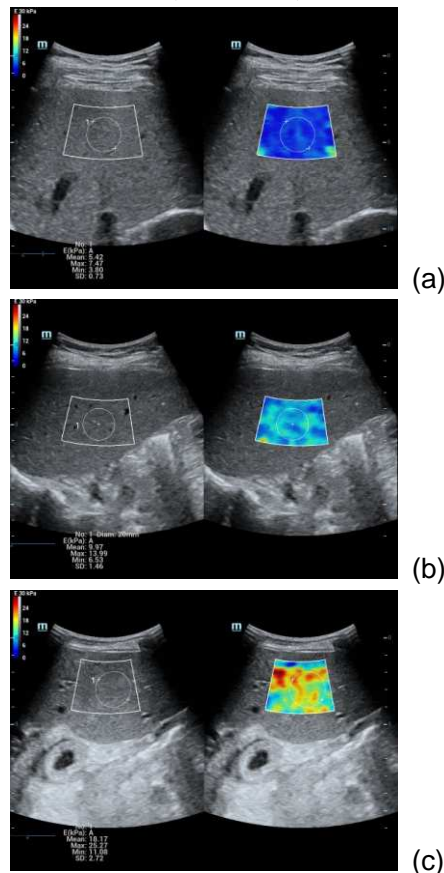


Figure 20 Images corresponding to different hepatic fibrosis degrees: (a) no hepatic fibrosis; (b) severe hepatic fibrosis; (c) hepatic cirrhosis

In the liver disease treatment center of a famous hospital in Shanghai, physicians used the STE function of the Resona 7 to conduct a clinical study on more than 300 patients with liver diseases, with pathogenic factors including HBV, HCV, DILI, and AIH. Physicians carried out the liver biopsy examination on

209 patients out of the 300 patients, including 88 patients experiencing HBV.

The liver STE examination is generally conducted from the right intercostal space. The STE measured values often fluctuate slightly due to the small contact surface of the probe plus the influence of patients' respiratory movement. Therefore, it is recommended to select the mean value of a round measurement area with the diameter greater than or equal to 10 mm as a single measurement result. It is also recommended to perform the measurement 3-10 times and use the median or mean value of the measurements as the final measurement result, so as to improve the accuracy and repeatability of the liver STE measurement.

In this clinical study, the Emean value was measured in a round measurement area with the diameter of 20 mm, and the median of measured values of five measurements was used as the final result. In the pathological examination, the staging results hepatic fibrosis are evaluated according to the Scheuer scoring system.

The study results show that the STE/STQ technology has great clinical value in assisting with the non-invasive diagnosis of early liver cirrhosis and the staging of liver fibrosis. The SET measured value increases with the deepening of liver fibrosis. Most patients suffering from cirrhosis have a Young's modulus greater than 11.3 kPa, and the Young's modulus of a majority of patients with severe liver fibrosis is within the range of 9.5 kPa to 11.3 kPa. For patients without or with mild liver fibrosis, their Young's modulus is mostly lower than 7.2 kPa or even below 6.4 kPa.

Figure 21 shows the statistics on the Young's modulus of examined 209 cases at different Scheuer pathological stages. It can be seen that there are obvious differences between the measurement results at different stages of

liver fibrosis. Use the demarcation of $\geq S4$ and $\leq S3$ as an example. The AUROC can be up to 0.95.

It is noteworthy that there are many overlapped areas between S0 no fibrosis and S1 mild fibrosis, as shown in Figure 22.

In addition, in consideration of the possible differences between various pathogenic factors, the liver Young's modulus of the 88 HBV cases is observed individually. It is found that the STE measurement result also increases with the deepening of liver fibrosis, as shown in Figure 23.

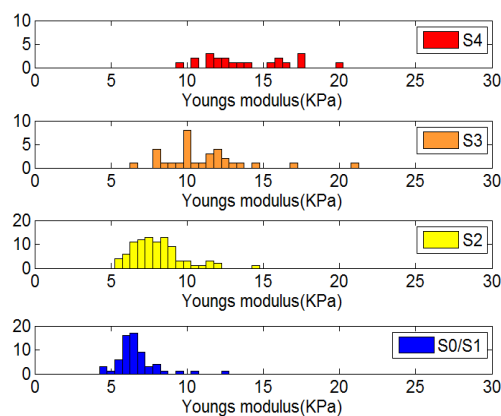


Figure 21 Distribution of Young's modulus value in different stages of liver fibrosis

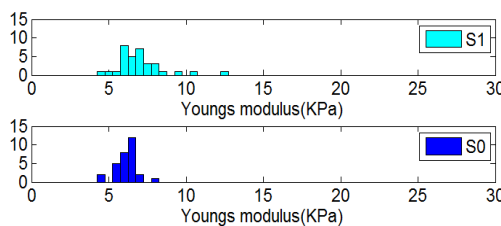


Figure 22 Distribution of Young's modulus value of S0 and S1 in liver fibrosis

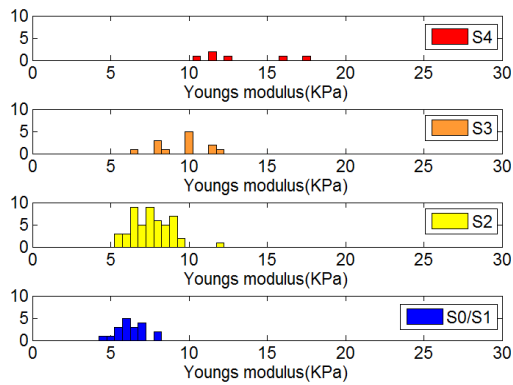


Figure 23 Distribution of Young's modulus value in different stages of liver fibrosis—HBV cases.

Conclusion

Mindray's STE/STQ for shear wave elastography offers a new method for obtaining quantitative tissue elasticity information for clinical ultrasound diagnosis. Based on the ultra-wide beam tracking imaging platform, STE/STQ can reach a shear wave elastography speed of up to 10 KHz per frame, which allows super fast detection of all necessary shear wave information in the ROI. By using better focused ultrasound beams, STE/STQ boasts, in addition to an ultra-high frame rate, an excellent penetration capability, which ensures better elasticity images and measurement results. In the clinical study, the STE technology was applied to the breast patients for the first time and showed highly significant results, although the scale of study was not very large. In particular, the shell analysis tool can provide valuable clinical information for the classification of whether a tumor is malignant or benign. In addition, the proprietary inter-frame joint statistics function greatly simplifies hepatic fibrosis degree measurement.

Currently, many hospitals are using STE/STQ for clinical researches on a broader area and more samples. We wish to provide more accurate clinical diagnosis reference indicator suggestions in the future, such as

elasticity measurement result boundaries of benign and malignant tumors as well as elasticity measurement result boundaries of different hepatic fibrosis stages, so as to better facilitate clinical diagnosis.

Reference

- [1] Ophir J, Cespedes I, Ponnekanti H, et al. Elastography: a quantitative method for imaging the elasticity of biological tissues. *Ultrasonic Imaging*, 1991, 13: 111-134.
- [2] L. Gao, KJ Parker. Imaging of the elastic properties of tissue – a review. *Ultrasound in Medicine and Biology*. 1996, 22(8), 959-976
- [3] Sarvazyan AP, Rudenko OV, Swanson SD, Fowlkes JB, Emelianov SY. Shear wave elasticity imaging: A new ultrasonic technology of medical diagnostic. *Ultr. Med Biol* 1998;20:1419 –1436.
- [4] sono-elastography: main clinical applications. Fabarizio calliada, mario canepari, giovanna ferraioli, carlo filice, 2012
- [5] Anke Thomas. Real-time sonoelastography performed in addition to B-mode ultrasound and mammography: improved differentiation of breast lesions? *Academic Radiology*. 2006;13(12):1496-1504
- [6] Anke Thomas. Real-time sonoelastography of the cervix: tissue elasticity of the normal and abnormal cervix. *Academic Radiology*. 2007;14(2):193-200
- [7] Jianqiao Zhou, Weiwei Zhan, et al. Stiffness of the surrounding tissue of breast lesions evaluated by ultrasound elastography. *European Society of Radiology*. 2014; DOI 10.1007/s00330-014-3152-7

- [8] JLGennisson,SCatheline, et al. Transient elastography in anisotropic medium:Application to the measurement of slow and fast shearwave speeds in muscles. J Acoustical Society of America. 2003;114:536-541
- [9] M. L Palmeri., M. H Wang. Quantifying hepatic shear modulus in vivo using acoustic radiation force. Ultrasound in Med & Biol. 2008;34(4):546-558
- [10] G R Torr. The acoustic radiation force. Am. J. Phys. 1984; 52(5)
- [11] Joyce McLaughlin and Daniel Renzi. Shear wave speed recovery in transient elastography and supersonic imaging using propagating front. Inverse Problems.2006; 22:681–706