



Technical White Paper

Plane-Wave Based Contrast-Enhanced Ultrasound Technology

mindray
healthcare within reach

Plane-Wave Based Contrast-Enhanced Ultrasound Technology

Zhang Xirui and Sang Maodong

Contrast Image Group of the Mindray Medical Beijing Research Institute

Overview

Due to the real-time performance, low cost, and high diagnosis rate, contrast-enhanced ultrasound (CEUS) plays an indispensable role in diagnosis of malignant diseases (such as the liver cancer, kidney cancer, breast cancer, and thyroid cancer) and evaluation after radiofrequency ablation. The key of the CEUS technology is that the non-linear echo generated by microbubble under acoustic field excitation is effectively received and used for imaging. Currently, the commonly-used microbubble, such as SonoVue, is made of the lipid shell and encapsulated inert gas. The microbubble has a diameter ranging from 1 to 10 μm , and complies with the Rayleigh distribution. The resonance frequency changes with the microbubble diameter. A larger diameter indicates a lower resonance frequency. If the diameter of the microbubble is 3.2 μm and such microbubble occupies a larger proportion, the corresponding resonance frequency is about 2.1 MHz. Under ultrasound excitation, microbubbles produce two types of physical vibration: contraction and expansion, which are caused by the positive and negative acoustic pressure. Expansion is the main factor that causes microbubble destruction. Clinically, the mechanical index (MI) is used to measure the expansion amplitude under acoustic field excitation. The MI formula is as follows:

$$\text{MI} = \frac{P_{\text{max}}^-}{\sqrt{f}} \quad (1)$$

In the preceding formula, P_{max}^- and f indicate the maximum negative acoustic pressure and transmit frequency, respectively. Currently, the real-time CEUS that is most widely used in clinical practice uses the typical low MI imaging mode. On the one hand, the low MI can prevent microbubbles from being destructed (in most cases, the MI value cannot exceed 0.1) to ensure that the process of microbubbles perfusion with the blood flow can be completely observed. On the other hand, the non-linearity of the human tissue is lower than that of microbubbles. When the MI is low, it is not easy to excite the non-linear components similar to microbubbles, preventing interference with the CEUS.

However, a low MI value is not mandatory for all CEUS applications. In the poor blood supply scenarios (such as the breast) or high-frequency CEUS scenario that is demanding on the penetration, traditional CEUS methods may face a technical bottleneck, that is, the penetration is mutually exclusive with the duration. Take the linear CEUS for example. The high-frequency probe transmits high-frequency signals for imaging, and the insufficient penetration is an inherent problem. Considering that the concentration of microbubbles that can reach the superficial organ is very low, the non-linear echo intensity obtained by the linear probe is far smaller than that of the Convex array/phased array probe with a low transmit frequency. In this case, the MI must be increased to enhance the CEUS signal strength and penetration. Consequently, microbubbles will be destructed, which shortens the CEUS duration and vice versa, as shown in Figure 1.

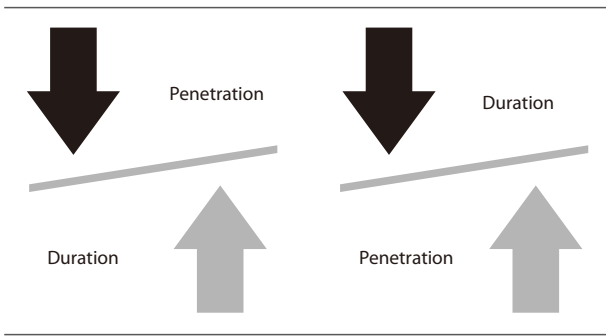


Figure 1 Technical bottleneck of the traditional CEUS

Plane-wave based contrast-enhanced ultrasound (PW-CEUS) is a new CEUS technology developed by Mindray. PW-CEUS adopts the full array transmission excitation and full field receiving imaging, and a complete image can be obtained with each plane-wave transmission. Compared with the traditional focused wave based CEUS (FW-CEUS), the PW-CEUS technology features less transmission times, which significantly reduces the intensity that microbubbles are excited within a unit frame. In this way, the single transmission intensity can be increased on the precondition that the microbubbles are not destroyed. Eventually, the penetration is improved without sacrificing the duration. In addition, the Resona7 platform based PW-CEUS technology adopts the coherent angle compounding method to effectively improve the spatial resolution and signal-to-noise ratio (SNR) of images.

The superficial probe of the Resona7 platform has been used for clinical verification of breast and thyroid imaging. The clinical results prove the outstanding superficial organ CEUS performance of the PW-CEUS technology.

Introduction to the PW-CEUS Technology

Basic Principles and Clinical Values of PW-CEUS

The major difference between the PW-CEUS and a traditional CEUS technology lies in the transmit and receive modes. As shown in Figure 2 (a), take the simplest single beam reception for example. In FW-CEUS mode, each time a receive line is obtained at the cost of one transmission. If a frame of image has N receive lines, N times of transmission are required. In contrast, in the plane wave mode shown in Figure 2 (b), a frame of image is obtained only after one full array non-

focused transmission, and the transmission cost is reduced by N times. Even if the focused wave uses the parallel multi-beam processing technology (2-beam, 4-beam, or 8-beam), the plane wave still excels the focused wave in the small number of transmission. For the CEUS, reduction in the number of transmissions can significantly decrease the intensity that microbubbles are excited by the acoustic field within a unit frame. This eventually reduces the microbubble destruction rate, and increases the CEUS duration. To improve the signal intensity, on the precondition that the microbubble destruction rate in PW-CEUS mode is consistent with that in FW-CEUS mode, the single acoustic field excitation intensity of the PW-CEUS can be increased. In conclusion, the PW-CEUS will greatly improve the signal intensity and duration of CEUS (especially for superficial organ CEUS).

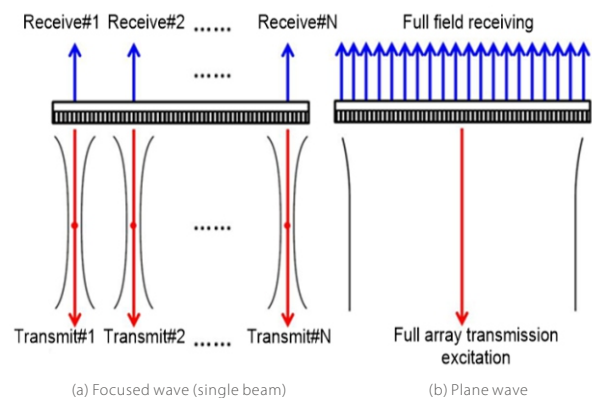
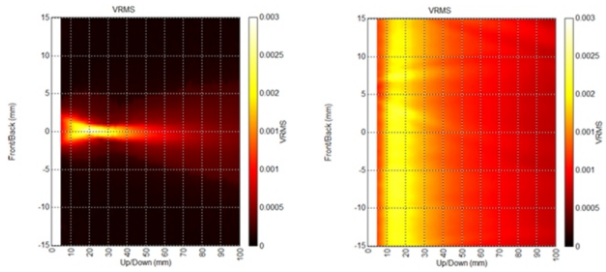


Figure 2 Difference in the transmit-receive mode between the focused wave and plane wave

Key to the PW-CEUS Image Quality: Coherent Angle Compounding Technology

However, the image obtained through each transmission of the plane wave has the problem of poor lateral resolution and low SNR at the medium-far field. Figure 3 illustrates the main causes. The plane wave uses the non-focused wide beam for transmission, and digital focusing is performed only at the receiving end. As a result, the sidelobe of the transmit-receive compounding beam is relatively high, which is reflected as the poor lateral resolution on the image. Comparison between Figure 3 (a) and Figure 3 (b) indicates that within the most commonly-seen depth range of 5 cm in superficial organ CEUS, the transmit acoustic field intensity of the PW-CEUS is equivalent to that of the FW-CEUS only at 1 to 2 cm, and the transmit acoustic field intensity of the PW-CEUS is lower than to that of the FW-CEUS at 2 to 5 cm. That is why the SNR at the medium-far field is low on a PW-CEUS image.



(a) Transmit acoustic field of the focused wave (b) Transmit acoustic field of the plane wave
Figure 3 Transmit acoustic fields of the focused wave and plane wave

To improve the lateral resolution and SNR at the medium-far field of the PW-CEUS image, the procedure of coherent angle compounding is added after the beamforming result is received and before envelope detection. This technology requires that the probe perform deflection transmission at a certain angle and quantity.

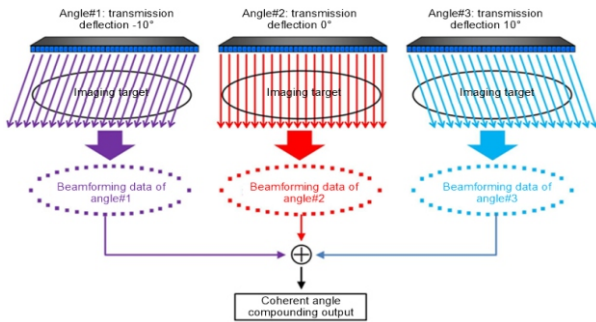
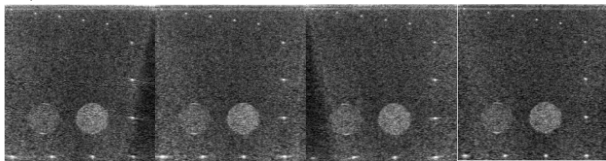


Figure 4 Coherent angle compounding of the plane wave

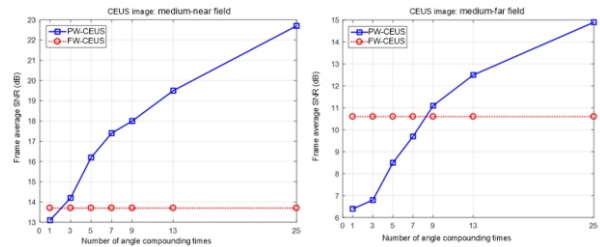
The schematic diagram in Figure 4 considers the simplest scenario: Perform deflection transmission for three times at the angles of -10° , 0° , and 10° , respectively. Beamforming is performed on the echo data at different angles for inherent angle compounding. The result is output to the subsequent envelop detection, logarithmic compression, dynamic range control, and DSC, and eventually the image is formed. To better learn the effect of the inherent angle compounding technology in improving the lateral resolution of the plane wave image, Figure 5 provides an example, in which the transmission angles ranges from -10° to 10° , the beam is deflected for 17 times, and the angle interval is 1.25° . After the coherent angle compounding processing, the lateral resolution (especially the target at the medium-far field) is obviously improved.



Angle#1(-10°) + ... + Angle#9(0°) + ... + Angle#17(10°) = Coherent angle compounding result

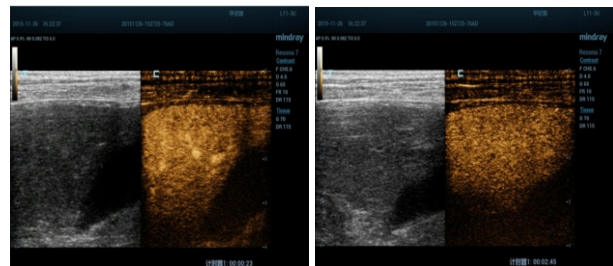
Figure 5 Effects of the coherent angle compounding (17 times) technology in improving the lateral resolution of the image

To quantify the improvement of the coherent angle compounding (17 times) technology in improving the SNR of the PW-CEUS image in comparison with the traditional FW-CEUS, we designed an animal experiment (liver of a 12 kg beagle dog; contrast agent injection dosage 0.05 mL/kg; L11-3U probe under the Resona7 platform), collect the front-end data of the PW-CEUS, and perform quantitative analysis on the data. The result is provided in Figure 6. At the medium-near field, when the number of compounding times reaches 3, the SNR of the PW-CEUS can excel that of the FW-CEUS; when the number of compounding times reaches 25, the advantage of the PW-CEUS reaches 9 dB. At the medium-far field, the SNR advantage of the PW-CEUS is relatively weak. When the number of compounding times reaches 9, the SNR of the PW-CEUS can excel that of the FW-CEUS; when the number of compounding times reaches 25, the advantage of the PW-CEUS reaches 4 dB. Figure 7 provides the direct comparison result of the animal experiment. After 25 times of compounding, the PW-CEUS signal strength is obviously better than that of the FW-CEUS under the same phase.



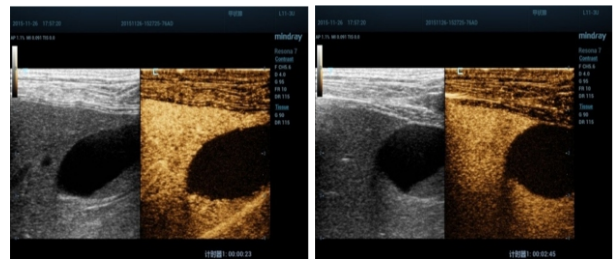
(a) Medium-near field: 0.92–2.31 cm (b) Medium-far field: 2.31–3.70 cm

Figure 6 Curve showing the change of the frame average SNR of the PW-CEUS with the number of coherent angle compounding times



(a) FW-CEUS: arterial phase

(b) FW-CEUS: delayed phase



(c) PW-CEUS: arterial phase

(d) PW-CEUS: delayed phase

Figure 7 Comparison of CEUS effects based on the animal experiment: PW-CEUS after 25 times of coherent angle compounding vs. FW-CEUS

It is worth emphasizing that although coherent angle compounding can improve the lateral resolution and SNR of the image, blindly increasing the number of coherent angle compounding times is not advisable due to the following reasons:

- (1) The data storage amount and calculation complexity on the receive end increase, which affects the frame rate.
- (2) The microbubble destruction rate significantly increases, which shortens the CEUS duration.
- (3) As shown in the SNR curve in Figure 6, the larger the number of coherent angle compounding times is, the less significantly the SNR is improved.

Clinical Application of the Resona7-Based PW-CEUS

Breast CEUS, thyroid CEUS, and evaluation after radiofrequency ablation of thyroid nodules are typical application scenarios of superficial organ CEUS. Mindray has added the PW-CEUS function to the superficial probe of the Resona7 platform and applied it to the preceding three typical clinical scenarios. The PW-CEUS function has been recognized and well received by doctors.

Breast mass; contrast agent dosage 2.4 mL;
L14-5WU and L9-3U are used

Ultrasound description: As shown in Figure 8, the subcutaneous fat of the breast is basically normal on both sides, and the gland thickness is basically normal. The echo of mammary tissue is even. The CFI indicates that no abnormal blood flow signals are seen inside the breast.

As shown in Figure 8, a 13.7x10.9 mm mass is seen at the 2 o'clock position of the left breast, and a 17.9x13.8 mm mass is seen at the 12 o'clock position of the left breast. The masses grow horizontally, are of irregular shape, and have edges. Low echo is found inside the masses and punctate strong echo is scattered. The rear part of the masses is accompanied with sound attenuation, the structures around the masses are distorted, and the catheter around the masses does not change significantly. The CFI indicates that rich blood flow signals are seen at the edge and in the center of the masses, and the blood vessels are thick and travel in a distorted

manner.

The comments from clinical evaluation on the PW-CEUS are as follows: As shown in Figure 9, both PW-CEUS-enabled probes can accurately describe the blood perfusion condition of the breast lumps, the CEUS intensity and duration are outstanding, and therefore the PW-CEUS is very helpful in clinical diagnosis.

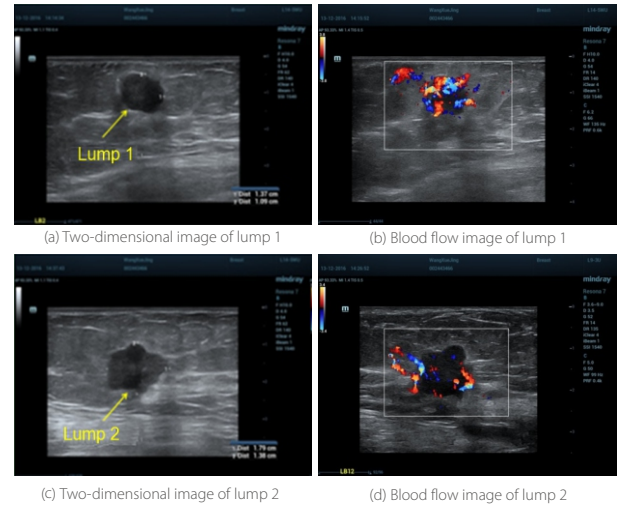


Figure 8 Two-dimensional image and blood flow image of the breast lump

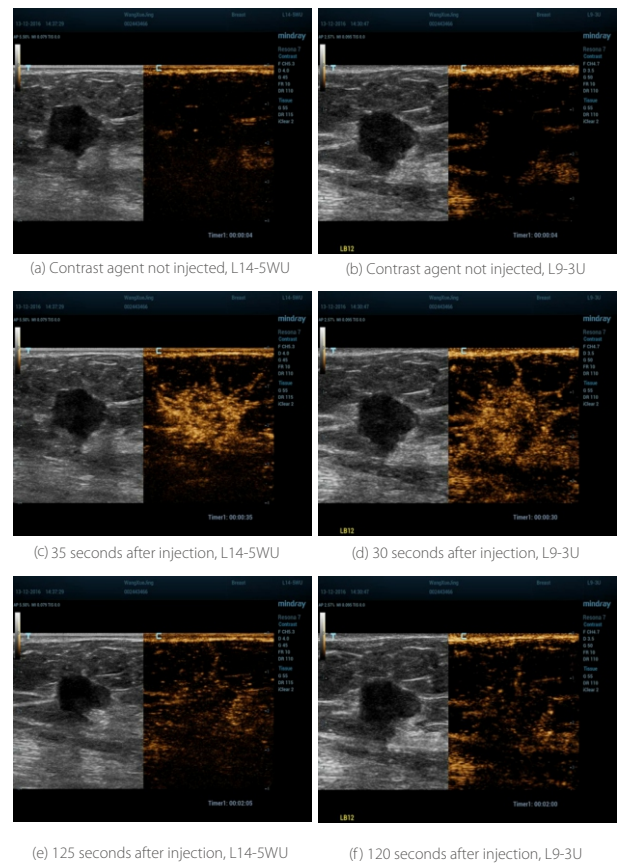
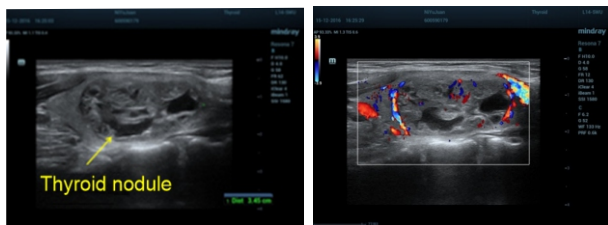


Figure 9 PW-CEUS images of the breast provided by the L14-5WU and L9-3U probes of the Resona7 platform

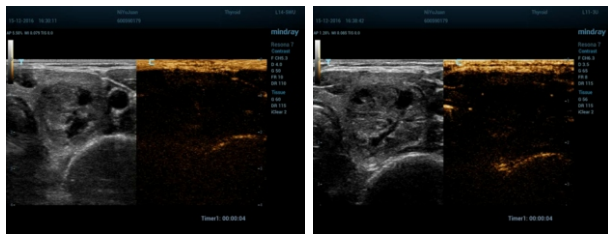
Thyroid nodule; contrast agent dosage 1.2 mL; L14-5WU and L11-3U are used

Ultrasound description: As shown in Figure 10, a mass with the left-to-right diameter of 23.3 mm, front-to-rear diameter of 16.2 mm, and the upper-to-lower diameter of 34.5 mm can be seen in the middle of the right thyroid. The mass grows horizontally and the edge is smooth. The internal structure is solid, medium echo is seen, and no calcification strong echo is seen. The CFI indicates that the mass shows mixed blood supply and the blood supply is rich.

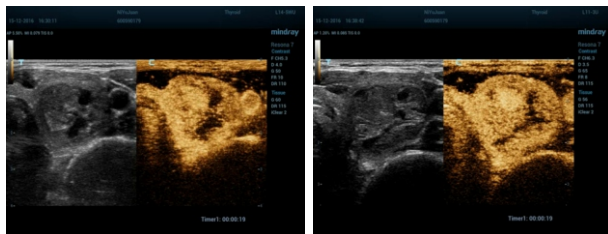
The comments from clinical evaluation on the PW-CEUS are as follows: At the dosage of 1.2 mL, the PW-CEUS technology demonstrates excellent sensitivity, and the CEUS intensity and duration are sufficient to help clinicians make accurate diagnosis.



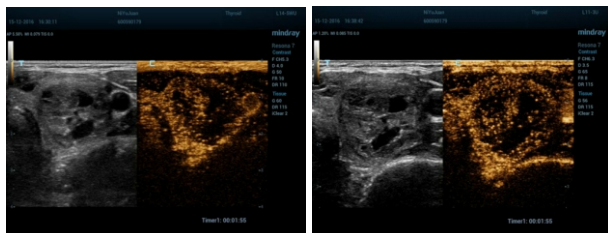
(a) Two-dimensional image (b) Blood flow image
Figure 10 Two-dimensional image and blood flow image of the thyroid nodule



(a) Contrast agent not injected, L14-5WU (b) Contrast agent not injected, L11-3U



(c) 19 seconds after injection, L14-5WU (d) 19 seconds after injection, L11-3U



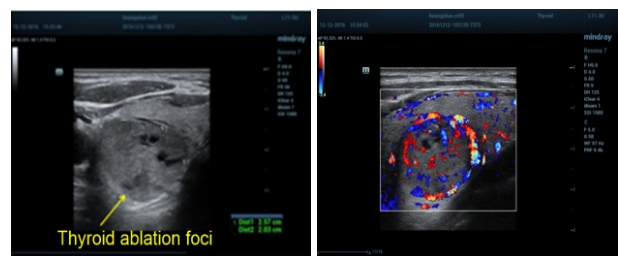
(e) 115 seconds after injection, L14-5WU (f) 115 seconds after injection, L11-3U

Figure 11 PW-CEUS images of the thyroid nodule provided by the L14-5WU and L11-3U probes of the Resona7 platform

Evaluation after radiofrequency ablation of a thyroid nodule; contrast agent dosage 2.4 mL; L11-3U is used

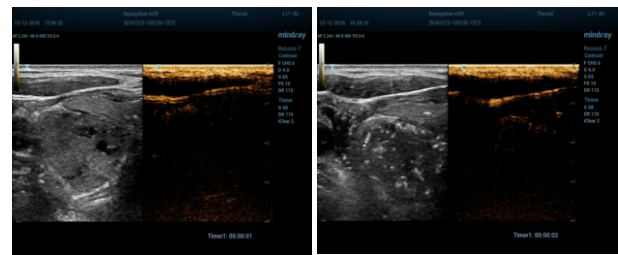
Ultrasound description: As shown in Figure 12, a mass with the left-to-right diameter of 25.7 mm, front-to-rear diameter of 20.3 mm, and the upper-to-lower diameter of 24.0 mm can be seen in the lower part of the left thyroid. The mass volume is 6.55 mL. The mass grows horizontally and the edge is smooth. The internal structure is solid, medium echo is seen, and no calcification strong echo is seen. The CFI indicates that the mass shows mixed blood supply and the blood supply is extremely rich. The fine needle is used to extract the mass for biopsy. The cellular pathology indicates that the mass is benign.

The comments from clinical evaluation on the PW-CEUS are as follows: As shown in Figure 13, PW-CEUS images obtained before and after radiofrequency ablation indicate that no contrast agent perfusion is seen in the center of the target nodule after radiofrequency ablation. This indicates that the operation is successful.

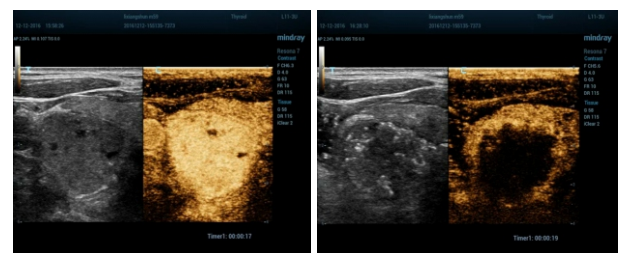


(a) Two-dimensional image (b) Blood flow image

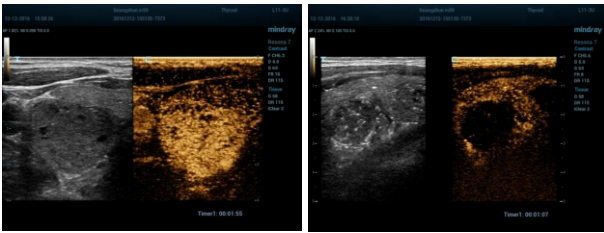
Figure 12 Two-dimensional image and blood flow image of the thyroid ablation focus



(a) Contrast agent not injected, before the operation (b) Contrast agent not injected, after the operation



(c) 17 seconds after injection, before the operation (d) 19 seconds after injection, after the operation



(e) 115 seconds after injection, before the operation (f) 67 seconds after injection, after the operation

Figure 13 PW-CEUS images provided by the L11-3U probe of the Resona7 platform before and after radiofrequency ablation of the thyroid nodule

Conclusion

CEUS plays an increasingly important role in diagnosing superficial organ diseases such as thyroid cancer, breast cancer, and carotid stenosis, as well as in evaluation after radiofrequency ablation of thyroid nodules. In the traditional superficial organ CEUS, the high-frequency linear probe is often used. Mismatching of its transmit frequency with the resonance frequency of microbubbles will lead to problems such as weak contrast signals and short duration, and therefore not able to provide clear and complete perfusion process for doctors. For organs with poor blood supply, such as the breast, how to improve the microbubble signals and duration have become challenges that need to resolve in clinical practice.

Under this background, after completing a series of development processes (including technical survey, theoretical analysis, engineering implementation, performance test, animal experiment, and clinical verification on human body), Mindray launches the PW-CEUS technology that is based on the high-frequency linear probe. The PW-CEUS breaks the bottleneck that the common superficial CEUS cannot improve the signal strength and duration at the same time. In addition, the PW-CEUS uses the multiple angle coherent compounding method to further enhance the spatial resolution and SNR of images.

As a new CEUS technology, PW-CEUS still has many aspects to be explored or improved, such as improvement of the multiple angle coherent compounding technology. Mindray will continue its efforts in improving technologies to promote development of superficial CEUS.

Mindray Building, Keji 12th Road South,
High-tech Industrial Park, Nanshan, Shenzhen 518057, P.R. China
Tel: +86 755 8188 8998 Fax: +86 755 26582680
E-mail: intl-market@mindray.com www.mindray.com

mindray | *healthcare with reach* are registered trademarks or trademarks owned by Shenzhen Mindray Bio-medical Electronics Co., LTD.
©2015 Shenzhen Mindray Bio-Medical Electronics Co., Ltd. All rights reserved. Specifications subject to changes without prior notice.
P/N:ENG-Technical White Paper-Plane-Wave Based Contrast-Enhanced Ultrasound Technology-210285X7P-20170705

mindray